



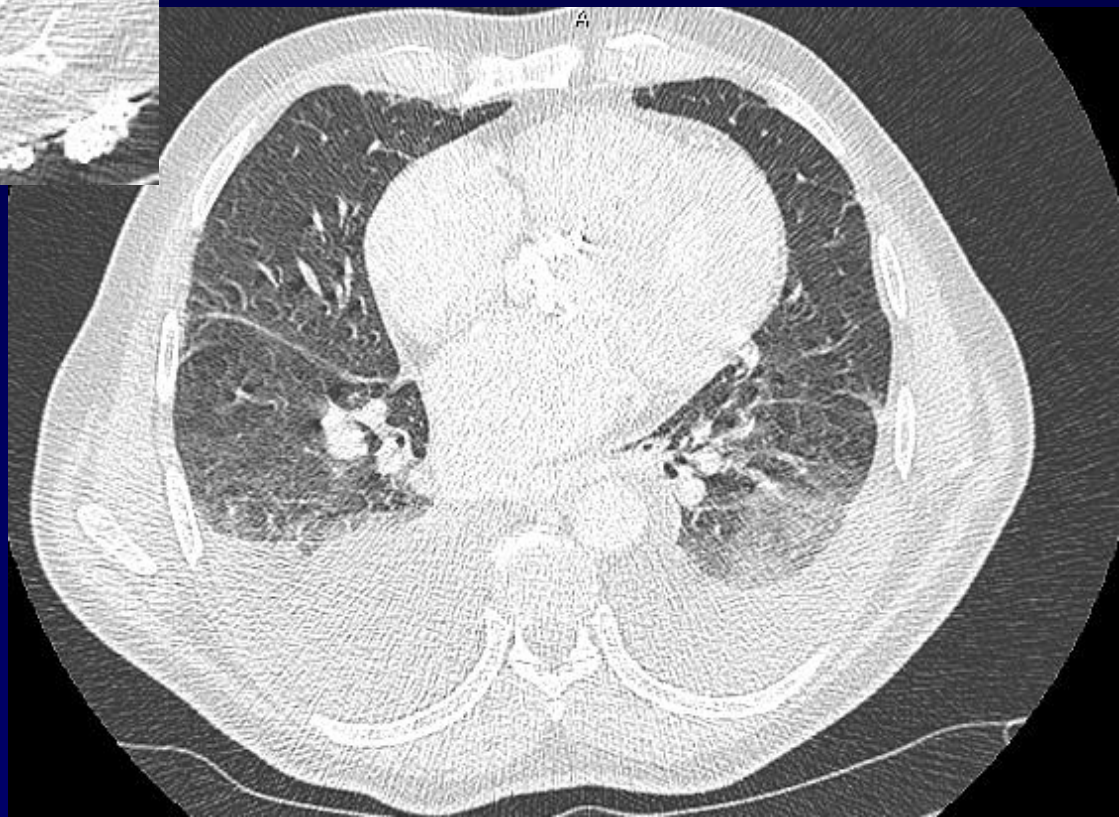
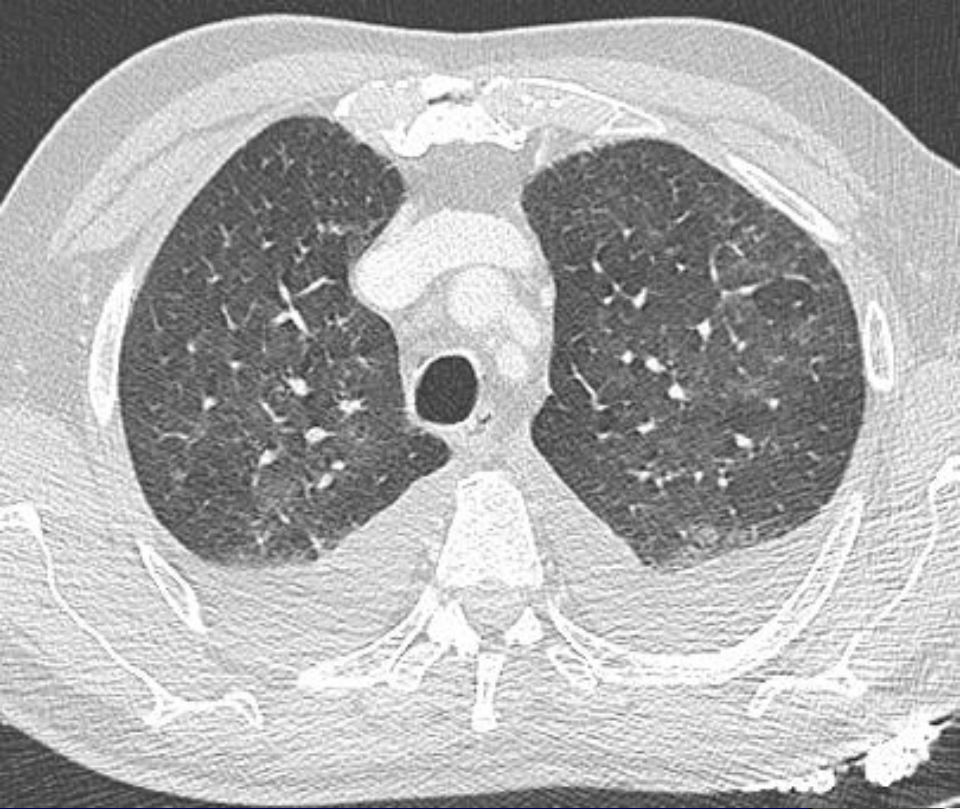
Lacout A

Patient de 67 ans

Dyspnée se majorant, stade II - III

Expectoration noirâtre

Aurait eu une Cs cardio il y a quelques semaines normale...





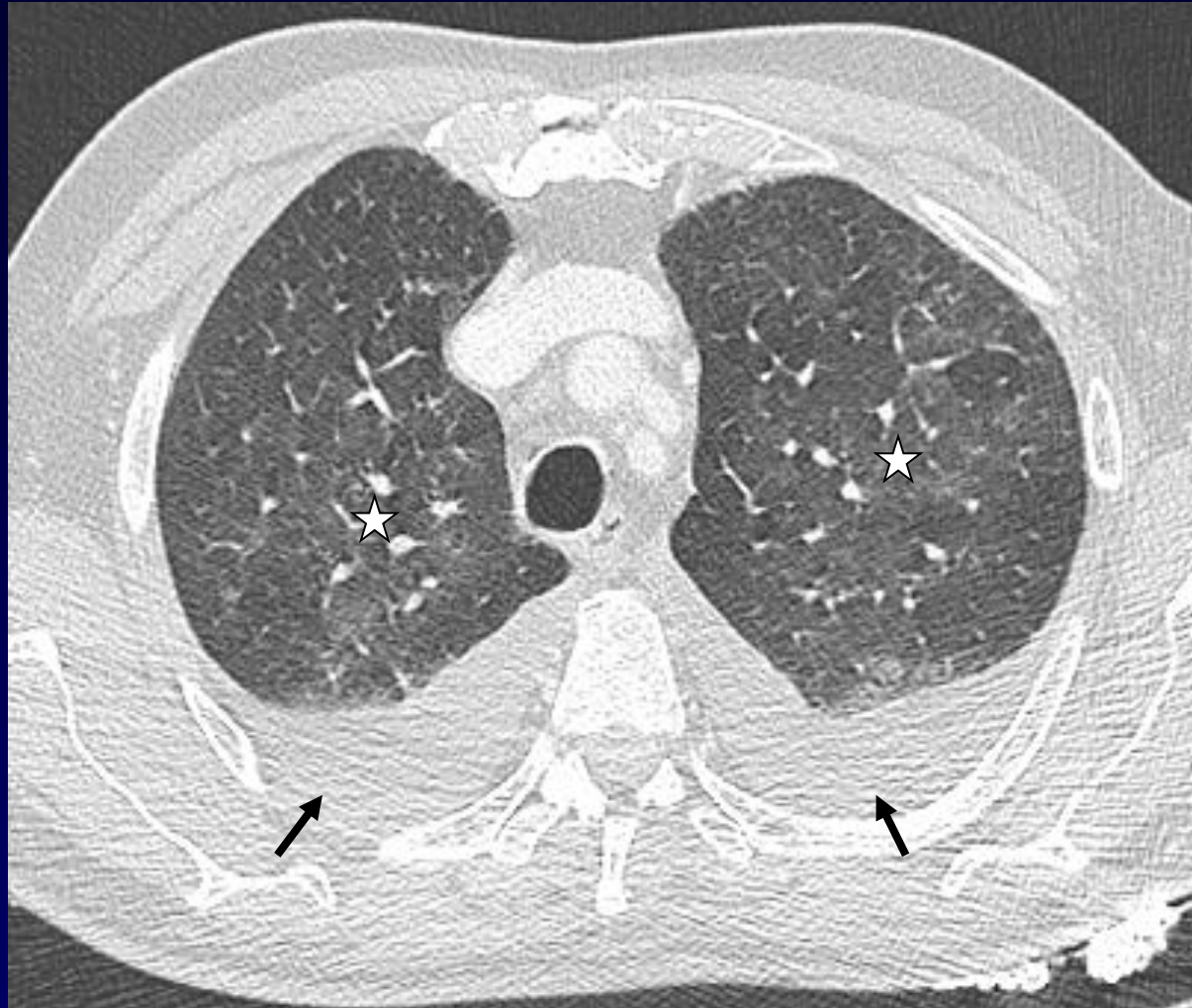
Diagnostic ?



Insuffisance cardiaque gauche

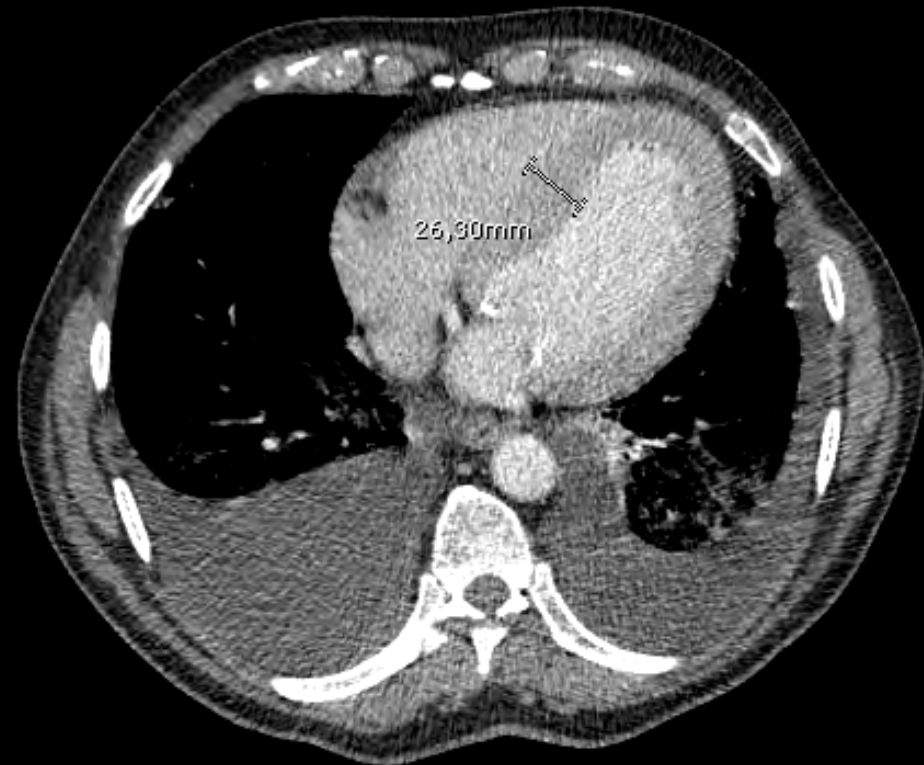
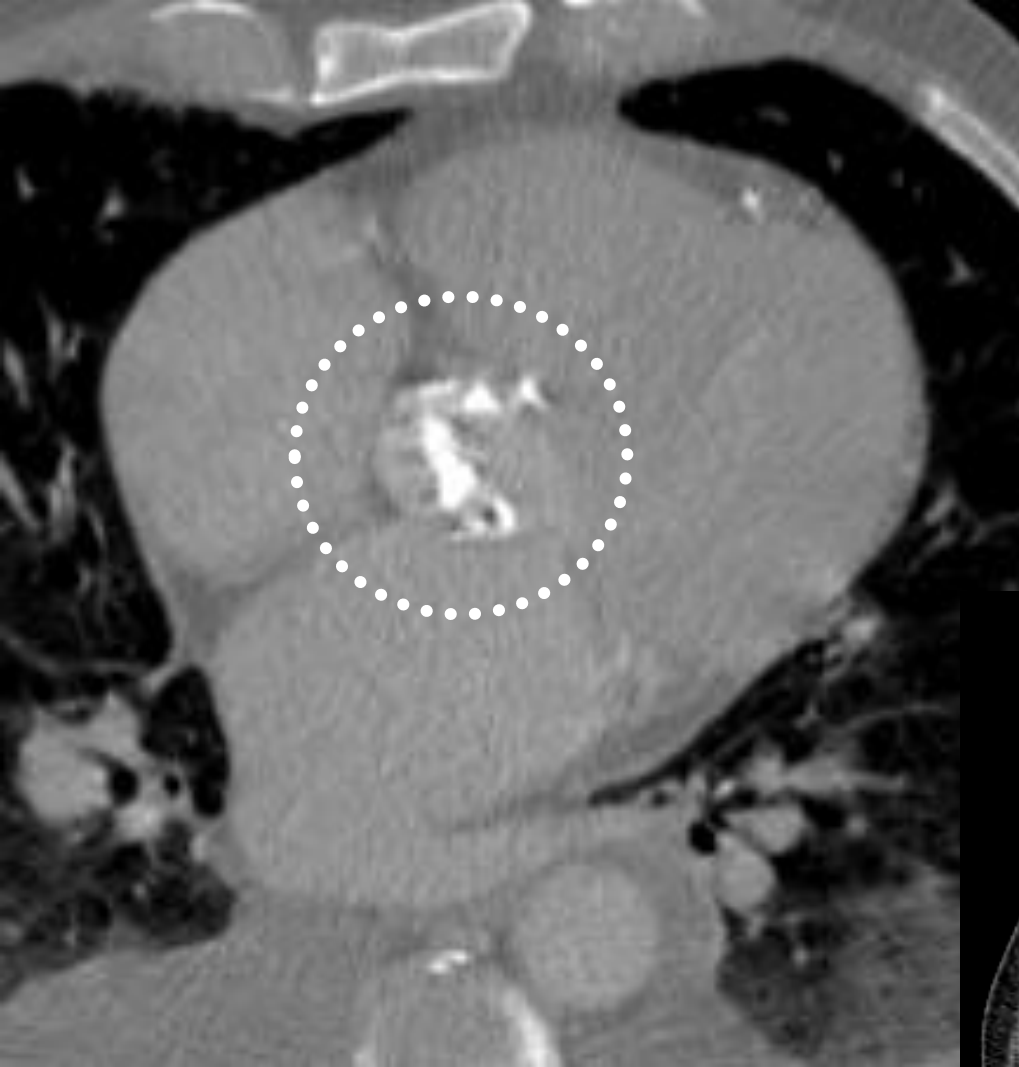
Œdème pulmonaire / Epanchement pleuraux

Rétrécissement aortique calcifié serré



Discret verre dépoli (étoiles): OAP

Epanchement pleuraux (flèches)



Calcifications de la valve aortique